

Animals Asia Foundation Report

Compromised health and welfare of bears in China's bear bile farming industry, with special reference to the free-dripping bile extraction technique

March 2007

Kati Loeffler, DVM, PhD
Email: katiloeffler@yahoo.com

Jill Robinson, MBE
jrobinson@animalsasia.org

Gail Cochrane, BVMS, MRCVS
gcochrane@animalsasia.org

Animals Asia Foundation, GPO Box 374, General Post Office, Hong Kong
[**www.animalsasia.org**](http://www.animalsasia.org)

ABSTRACT

The practice of farming bears for bile extraction is legal in China and involves an estimated 7,000 bears, primarily Asiatic black bears (*Ursus thibetanus*). This document describes bear farming in China, with an emphasis on the health and disease of the bears and the long-term effects of bile extraction. Gross pathology of the gall bladder and surrounding abdominal tissues is described. The data presented here establishes the inhumanity of bear bile farming on the grounds that it severely and unavoidably compromises the physical and psychological health of the bears and that it violates every code of ethical conduct regarding the treatment of animals. All considerations of ethics, wildlife conservation, veterinary medicine and, ultimately, economics, lead to the conclusion that bear bile farming is an unacceptable practice and must end.

INTRODUCTION

Bears farmed for extraction of their bile are generally confined to cages the size of their bodies; are deprived of food, water and movement; suffer chronic pain, illness and abuse; and live with holes in their abdomens, from which the “liquid gold” of a multi-million dollar industry flows.

Bear bile farming is legal in China and involves an estimated 7,000 bears, primarily Asiatic black bears (*Ursus thibetanus*). In Vietnam, the practice was outlawed in 1992, although loopholes in the law and a lack of enforcement of the regulations have allowed the number of bears illicitly used for bile extraction to increase 10-fold to a current estimate of 4,000 bears. The practice of farming bears for their bile began in North Korea, although figures for bear bile farms and the bile trade there are presently unavailable. Bile extraction from bears is illegal in South Korea, where an estimated 1,800 bears are kept on farms. South Korean law allows farmed bears to be slaughtered for their parts at the age of 10 years.



Caged bear, Sichuan Province, China.

Animals Asia Foundation (AAF) is a non-governmental charitable organisation whose primary mission is to end the practice of farming bears for bile extraction in China and Vietnam (www.animalsasia.org). In July 2000, the China Wildlife Conservation Association and Sichuan Forestry Department agreed to assist AAF in the rescue of at least 500 bears from Chinese bear farms. This agreement was endorsed by China’s State Forestry Administration (then called the Ministry of Forestry). AAF’s rescued bears come from farms primarily in Sichuan Province, which has the largest number of bear farms. The bear farm owners agree to stop bile farming and relinquish their licences, as well as the right to new licences. The farmers receive fair compensation from AAF to begin a new livelihood. As of March 2007, AAF had rescued 219 bears for rehabilitation at the Sichuan Long Qiao Black Bear Rescue Centre (hereafter AAF Bear Rescue Centre) in Sichuan Province, China.

Bears usually arrive at the AAF Bear Rescue Centre stacked chaotically in tiny cages on the back of a truck: starved, sick and frightened. AAF veterinary staff triage the bears by thorough physical examination and laboratory workup and take critical cases to surgery immediately. The priority with the other bears is to provide them with a safe and compassionate environment, plenty of good food, water and medical care. As the bears gain strength and confidence, they are taken to surgery for removal of their gall bladder, castration (males) and treatment for any other surgical conditions (described below). Post-operatively, the bears receive a great deal of medical attention, in addition to intensive husbandry and behavioural enrichment. After several months, when their abdomens and other wounds have healed, the bears move to dens, where they are integrated with other bears of compatible size, disability and temperament. Once the groups are stable, the bears are introduced to outdoor enclosures



Health check of a rescued bear by AAF’s veterinary team at the AAF Bear Rescue Centre, China.

(often for the first time in their lives) for rehabilitation. They then live out their lives in large, semi-natural, indoor-outdoor enclosures with a highly enriched environment and close monitoring of physical and mental health.

The bile farm bear rescue project has enabled AAF to accumulate a large amount of information about bear farming in China, specifically with regard to the health and disease of the bears obtained from these farms and the long-term effects of bile extraction and survival of these animals under bear farming conditions. Observations presented here are based on AAF's visits to more than 50 bear farms throughout Asia (more than half of which were at the official invitation of the governments of China, Vietnam and South Korea); countless interviews and meetings with bear farmers, Chinese officials, TCM practitioners and vendors dealing in bear parts; lectures and discussions at conferences; and thousands of hours of working with the bears received by the AAF Bear Rescue Centre. The medical data presented primarily in the last section are compiled from AAF's clinical records.

The data define bear bile farming as an unethical practice that severely and unavoidably compromises the physical and psychological health of the bears and violates every code of humane treatment of animals. All considerations of ethics, wildlife conservation, veterinary medicine and, ultimately, economics, lead to the conclusion that bear bile farming is, in every regard, an unacceptable practice.

BEAR BILE FARMING IN CHINA

Bear bile is used in Traditional Chinese Medicine (TCM) for its “bitter” and “cold” properties to cool “hot” regions of the body, to relieve spasms, to remove “cloudiness” from the eyes, for liver-related ailments and to purge worms from the intestinal tract (Pong et al., 1999; Lee, 1999; Liu, 2004). The TCM pharmacopoeia also lists a large variety of herbal products for each condition that may be treated with bear bile. Professor Liu Zhengcai, National Director of TCM Academic Inheritors in China, reviewed the use of bear bile over the 2,000 years of recorded TCM and concluded that it was “utterly unnecessary” as there were “many Chinese herbs with the same kind of nature and flavour [as bear bile]”.



Professor Liu Zhengcai supports the use of herbal products to replace bear bile.

The same conclusion has been reached by other practitioners involved with TCM (the Association of Chinese Medicine and Philosophy, 1994; Wang, 1994; Pong et al., 1999; Roberts, 1999). The active ingredient in bear bile, ursodeoxycholic acid (UDCA), is also produced synthetically for use in allopathic (Western) medicine. Despite the often superior herbal products listed in the TCM pharmacopoeia and the availability of pure, synthetic UDCA, the cultural conviction of the supremacy of bear bile remains strong among Asians worldwide. Demand for bear bile has soared as a result of increased production and the rising economic status of the Chinese, Japanese and South Koreans in particular.

The Chinese government first adopted the Korean practice of bear bile farming in the 1980s with the claim that it would protect wild Asiatic black bear populations by satisfying the market demand with farmed bile. In 1989, the government banned the removal of bears from the wild by hunting or live capture. Bear farms were to be self-sustaining or to purchase captive-bred bears from other farms. However, Asiatic black bears remain under Chinese Class 2 protection status, leaving a loophole that allows bears to be removed from the wild with “special” permits from local authorities. Chinese Class 2 species include endangered CITES I listed species such as Asiatic black bears and red pandas.

The lack of reliable data on the population or distribution of Asiatic black bears in China makes it difficult to evaluate whether bear farming meets the goal of preserving wild populations. Methodologies used in previous population estimates and the results of those studies have varied so greatly that there have been no reliable figures on which to base any argument. Wild bear populations in China may be threatened, they may have increased in some areas with the government's establishment of nature reserves (the “Grain to Green” programme of the 1990s), or poaching may be at a sustainable level and the population stable (Garshelis, 2002). We have insufficient information to assess the situation accurately. Dr. Dave

Garshelis, Co-chair of the IUCN Bear Specialist Group and renowned bear biologist, noted in a letter to the *China Daily* at the beginning of this year: “The truth is that we do not know whether bear farming saves any wild bears. We know that huge surpluses of farmed bile are produced; yet we also know that poaching of wild bears continues because wild bile is more valuable than farmed bile. The truth is that nobody really knows how many wild bears live in China, nor how many are being poached every year.” The first comprehensive population distribution study began in 2005 in Sichuan Province as a joint venture among scientists at the Peking University in Beijing and the Smithsonian Institution and the Minnesota Department of Natural Resources in the United States.

Meanwhile, evidence from numerous sources suggests that poaching continues in spite of bear farming and that it may even have increased (van Biema, 1994; Roberts, 1999; Maas, 2000; Phillips and Wilson, 2002; Williamson, 2002). AAF estimates that 21% of its bears that were born after the 1989 ban on wild capture are wild-caught. Wild-caught brown bears (*Ursus arctos*) are also found on bear bile farms in the northern provinces, despite the fact that Chinese regulations specify that only Asiatic black bears are to be used in bear bile farming. Sun bears (*Helarctos malayanos*) are occasionally found on bear farms as well. One Sichuan bear farmer, whose breeding programme was unsuccessful, admitted to AAF staff that he was paying villagers to bring him cubs from the forest. Villagers who live in bear habitat, poachers and nature reserve staff in China confess that poaching is not uncommon, that the chances of apprehending a poacher are slim and that the punishment, if one is caught, fails to deter both existing and potential poachers. Bear poachers in China commonly use poisoned bait or snares. The latter is a means to capture cubs that can be sold to farms or zoos, or as pets, and which, if the bear is caught alive, often causes at least the loss of a limb. Bombs may be used to kill wild bears as well.



Freedom was snared in the wild after the 1989 ban.

Bears throughout East Asia, Russia and North America are also poached for the Asian market (Berkhoudt, 1999; Roberts, 1999; Phillips and Wilson, 2002; Raloff, 2005). Again, the odds of getting caught even in North America are evidently worth the risk. Legal loopholes and relatively mild punishments for poaching or trafficking in bear parts allow the practice to thrive (van Biema, 1994; Roberts, 1999).

Driving these legal and illegal practices, of course, is a very lucrative market for bear bile, particularly for bile from wild bears. Bear products are consumed as a source of strength and status in China. Cultural perception elevates the potency of wild bear products above that of captive bears and consumers are willing to pay the difference. In the late 1990s, a kilogram of bile from a farmed bear cost US\$3,000, while bile from a wild bear cost approximately US\$16,000/kg on the Chinese black market (Ge Gabriel, 1999). With such a price differential, poaching of wild bears is far from under control and the production of farmed bear bile may, if anything, have made it worse (Roberts, 1999).

Thus, a two-tier market effect appears to have developed as a result of bear bile farming, spurred by the synergism of a perceived psychological “need” for, and an increased availability of bear bile and bile products. Traditionally, the use of bear bile in TCM was sparing: it was a rare product reserved for extreme cases or particularly wealthy patients. However, the commercial production of bear bile has flooded the market and bear bile is now found in products that have no relevance to TCM, such as shampoos, tonics, wine, soda, face creams and toothpaste. **The market feeds on the cultural assumption that bear bile must improve any product, even if there is neither traditional precedent nor scientific support for the suggestion. The ubiquitous availability of bear bile has therefore increased consumption and furthered demand. Paired with this increased demand is the burgeoning Chinese economy, which enables consumers to afford not only farmed bile, but the “real stuff” – wild bear gall.**



Bear bile is increasingly being used in non-medical products, such as wine, soda and tonics.

Despite the high consumption, nearly half of the 7,000 kg of bile produced annually on Chinese bear farms is surplus, according to government figures. International trade of CITES I listed wildlife species and their products is illegal and official sources in China are vague about what happens to the annual surplus of 3,000 kg of bear bile. However, there is ample evidence that a robust black market trade exports bile over the borders. Indeed, Chinese bear bile products feed the TCM trade throughout North America, Europe, Korea, Japan and Southeast Asia (Ge Gabriel, 1999; Phillips and Wilson, 2002). The foreign market, moreover, brings an estimated US\$30 million per year *more* than the bear products would gain on the Chinese domestic market. In Japan, for example, a kilo of bear bile powder cost more than US\$252,000 in 1999 (Phillips and Wilson, 2002).

The official figures on the number of bear farms and bears in China were, until 2005, 247 farms holding 7,002 bears. In January 2006, the State Forestry Administration announced that, as a result of its recent clean-up of the industry, there were now only 68 farms holding the same 7,002 bears. Despite a recent trend that has seen the consolidation of bear farms, the new figures are difficult to understand. Just two years ago, an official in Jilin Province reported to Animals Asia's investigators that the province's Yien Bien district alone had at least 70 bear farms containing more than 2,100 bears - with only 11 farms actually owning a licence. Recent information obtained by AAF shows that the number of bears on a farm still ranges from two or three to 3,000 or more. Moreover, the official figures do not take into account the many unlicensed bear bile production units, which may include one or two bears in cages behind a restaurant or at a peasant commune, or the possibility of surreptitious harvesting of bile from bears at zoos and wildlife parks.

Chinese law forbids the trade in any bear parts other than the domestic sale of products made of farmed bear bile. Nonetheless, AAF and others (e.g., TRAFFIC and World Society for the Protection of Animals) have documented the illegal trade in parts from slaughtered bears in addition to the trade in live bears for farms, wild bear bile and international trade in Chinese bear bile. Whole gall bladders, bear meat, paws and pelt may all be purchased. Bear paw soup or meat are offered in restaurants, particularly in those associated with some of the bear farms that invite tourism or those in rural areas where bears are poached. In May 2006, AAF personnel were told by the owner of a bear farm in Sichuan Province that his restaurant at the site of the farm served bear meat and paws: a customer had only to give a half hour's notice to order the dish. It has been documented that a request for bear paws at a bile farming operation results in the presentation, after a few minutes, of paws freshly severed from a live bear (Phillips and Wilson, 2002). Bear fat soaked in wine (known as "bear fat bones") is also found in TCM pharmacies; one retailer in southwestern China stated openly that he had obtained his product from bear farms.

Regulations for the care and treatment of bile farm bears are not enforced, in part, says the government, because they are "only regulations" and therefore cannot be enforced. Nonetheless, public concern about the operation of bear farms had sufficiently discomfited the government that, even in 1993, the Chinese Ministry of Forestry (now the State Forestry Administration) officially stopped issuing new licences for bear farms under a document entitled "Urgent notification to straighten out bear farms". This mandate also appears to be less than airtight, as AAF recently received bears from a farm whose owner said that he received his first licence in 2001. In 2005, the Chinese government commissioned a survey of bear farms in the country with the express intention of identifying unlicensed farms, as well as farms that did not meet "standards" of operation. The results of the survey and its repercussions have not been released to date – other than the sudden reduction in the official number of bear farms from 247 to 68 in January 2006.

The only laws pertaining to animals in China are those written to protect animals in the wild. Once wild (or domestic) animals are in captivity, there is very little to ensure their proper care. Of the more than 30 Chinese bear farms that AAF staff have visited, only two met the Chinese regulations and none came even close to Western standards for the humane treatment of animals.

An argument is occasionally made that the bears do survive on these farms, sometimes for years, and that their survival implies a reasonable level of care of the animals. This assumption is based on faulty reasoning and is incorrect. Many domestic and wildlife species survive under deplorable conditions and generate enough income to make the operation profitable (albeit not optimally). Good husbandry is, unfortunately, not a prerequisite for animals to survive and to generate bile, musk, antler

velvet or fur. Harvest of such products does not require good animal health, unlike on a dairy farm, where poor nutrition and husbandry will result in a lower milk yield. This is particularly true of a species such as the bear, which has evolved an incredible capacity to withstand periods of hardship, and of a product such as bile, which the body produces regardless of health status. All a bear bile farmer needs of his animals is for them to be alive. While the lifespan of captive bears in Western facilities is usually 25 to 30 years or more, bears on bile farms rarely live to even half that age.

WELFARE OF BEARS ON CHINESE BEAR BILE FARMS

Bear bile farming in China violates all of the Five Freedoms of Animal Welfare on which developed nations base their treatment of animals.

1. Freedom from hunger and thirst

The large majority of bear farms do not allow bears free access to drinking water, and those that do, restrict access to certain times of day or week. Bear farmers starve bears in order to save money and because nutritionally stressed bears yield more bile. The bears received at the AAF Bear Rescue Centre are usually underweight or even emaciated, eat ravenously, are frantic for water and have abnormal hair coats. In a species that is, as stated earlier, uniquely adapted to withstand privation, this indicates severe and long-standing malnutrition. Some bears arrive at the AAF Bear Rescue Centre with life-threatening nutritional deficiencies, such as calcium/phosphorus imbalances. It takes weeks or even months for these animals to display normal eating and drinking behaviours.



Bear on a farm, Yunnan Province, China, 2004.

2. Freedom from discomfort

Chinese regulations state that bears are to be given space to move about at all times except for the brief period every day when they are in cages for bile extraction. The reality is that many bears spend their entire lives in the “extraction cages” and are never let out. Some farms have a small, bare, concrete enclosure in which some of the bears may move about, but inspection of those areas reveals that bears are rarely allowed access to the space. Bear farmers at a farm in Heilongjiang Province openly stated to visitors that they kept the bears in the cages because they were much easier to manage that way. The bears were also not allowed into the enclosures, they said, because of the risk of infection in the fistula (P. Li, unpublished data). There is no effort to



Bear farm in Sichuan Province, China, Jan 2004.

provide the bears with areas in which they may feel comfortable and secure, or in which they may rest, play, mother, exercise or engage mind and body in a manner consistent with the biology and natural behaviour of the species.

3. Freedom to express normal behaviour

Normal bear behaviour does not occur on bear bile farms. Enclosures are far too small to meet the requirements of bears and there is no effort to provide them with any stimulus to encourage normal activities. Captive black bears exhibit socially interactive behaviour when housed in groups, but the intensive management required for maintenance of bear groups requires skills and expertise for which Chinese bear farmers show neither the interest nor predilection. **The bears on these farms are, moreover, hungry, thirsty, bored and sick, and associate humans with pain. Their reaction to people is therefore usually aggressive (fear-aggression). For these reasons, bears are usually housed alone in cages that are physically restrictive. Living space for the bears is thus insufficient and deprived of all but negative stimuli.**

Cubs are weaned unnaturally early for the species (three months or less, instead of 18 to 24 months as in nature), which deprives the mother of normal maternal behaviour and the cub of normal physical, social and psychological development. Weaned cubs are often raised in isolation because of the inability on the part of the farm staff to manage infectious disease.

These young bears exhibit a high level of abnormal behaviour that includes sucking on their own fur and paws, humming, stereotypic licking and pacing. Cubs housed together will often suckle on one another while emitting a low, humming vocalisation similar to what they would do when nursing on their mothers. Adult bears that have come from bear farms periodically display this behaviour as well. Cubs may be placed alone into wire cages and left to grow into the restrictive space. This has been seen to result in physical, not to mention psychological, developmental abnormalities in numerous bears.



Cubs are removed from their mothers at three months or less on the farms.

Environmental enrichment for animals as intelligent and active as bears requires the considerable expertise and intensive management of skilled professionals. Not only is such expertise rarely found in China, a good enrichment programme is also expensive. The space, environment and stimulus necessary for bears to express normal behaviour are therefore not found, nor will they be found, on bear farms.

4. Freedom from fear and distress

Fear of people is evident in the majority of the bears that AAF has visited on bear farms and that arrive at the AAF Bear Rescue Centre. Hunger, thirst, pain, physical abuse, deprived environments and chronic illness (described below) constitute distress.

5. Freedom from pain, injury or disease

The medical consequences of gall bladder fistulation and bile extraction are the primary focus of this document and will be discussed in detail below. Briefly, fistulation of a bear's abdomen for bile extraction involves the creation of a hole in the abdominal wall and in the gall bladder. The holes are secured into apposition and their communication kept patent with the use of a variety of methods described below. The surgeries to create the fistulas are conducted under thoroughly inappropriate conditions, and the training of the people performing the surgeries and providing the veterinary care for the bears is grossly inadequate. Surgery is rarely performed aseptically, the fistulas do not heal properly and the bears suffer chronic illness as a result.



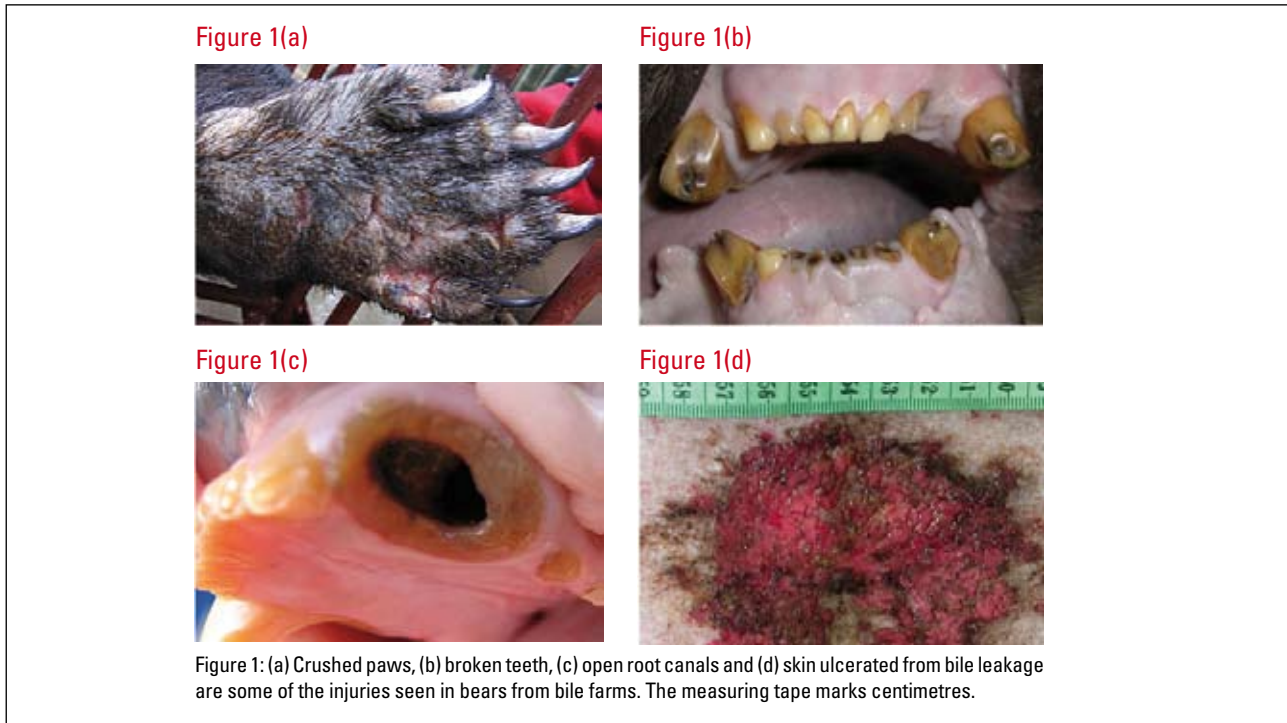
Many of the cages are excruciatingly small.

The construction of the extraction cages and direct observation of the extraction procedure indicate that, for the most part, bears have to be forcefully restrained to extract bile. Some cages are restrictively small so that the bear is forced to crouch down; others use a crush facility built into the top or sides of the cage. AAF has observed bears crushed flat in such cages for hours and, according to the farmers' own admissions, weeks on end.

A farmer often has to make repeated attempts to insert the catheter into the fistula. If the hole is beginning to heal shut between extractions, he or she thrusts a collecting tube through the hole to break down obstructing tissue. Farmers have described inserting a "red-hot metal probe" to pierce and scar a stubborn blockage. This, of course, results in trauma and pain. AAF's observations demonstrate that gall bladder fistulation surgeries and bile extraction performed on the bear farms significantly increase the risk of disease in the bears and must, by nature of the lesions, cause pain.

It must be emphasised that a fistulated gall bladder establishes an open communication between a normally sterile abdominal organ and the outside environment. In Western countries, this procedure and subsequent state would be allowed only for research purposes in laboratory animals under strictly regulated conditions and a clinically sterile post-operative environment. At the termination of the experiment, the animals would be euthanised due to the prohibitive expense and ethical considerations of maintaining living creatures with a gall bladder fistula.

Of the bears received at the AAF Bear Rescue Centre, 60% have missing limbs, mutilated digits from botched attempts at declawing, crushed paws, significant areas of scarring on the body and other signs of major injury (Figure 1). Visitors to bear farms report hearing bears pawing the cage and screaming during the bile extraction procedure (AAF, unpublished data; Robinson, 1994).



Dental problems associated with the practice of cutting canine teeth (to reduce the danger to the farmer), malnutrition and chewing on metal cage bars out of psychological distress occur in 25% of the bears received at the AAF Bear Rescue Centre (Figure 1(b) and (c)). Tapped bears (bears with fistulas) also appear to have a relatively high frequency of vision loss due to a variety of causes. Most common is the development of cataracts in one or both eyes (found in 4% of the tapped bears at the AAF Bear Rescue Centre; not found in any untapped bears). One bear became blind following chronic uveitis that did not respond to systemic or topical therapy. Another bear's blindness appears to have had a cerebral etiology. Whether the pathogenesis of these conditions involves consequences of gall bladder disease is unclear and needs to be investigated.

Infections in bears received at the AAF Bear Rescue Centre are resistant to nearly every antibiotic available in China, indicating 1) that the bears suffer chronic infections at the farms for which they require treatment; and 2) that use of antibiotics on bear farms is ubiquitous and inappropriate. Clearly, the bears on bear farms are not without pain, injury and disease.

Maintenance of animals under conditions free from pain, injury and disease, particularly if those animals undergo the physiologic stress of surgery, bile extraction and chronic infection of bile farm bears, necessitates the availability of high-quality veterinary care. This is rarely available for Chinese bear bile operations because experienced and expert veterinary services are difficult to find in China and are expensive. Moreover, a well-trained veterinarian is unlikely to compromise his or her principles by working for, and thereby supporting the animal abuse, that characterises the bear farming industry.

Most veterinary care on bear farms is provided by the bear farmers themselves. Veterinarians are usually employed only on very large farms or only to perform the gall bladder fistulation surgeries. In addition, Chinese-trained veterinarians have openly acknowledged their frustration with deficits in their training to AAF's and other Western-trained veterinarians. Graduates of the highest-ranked veterinary college in the country consider the level of training for veterinarians in China

and the quality of veterinary medicine and surgery that is practised to be at least 30 years behind Western standards (personal communication to Jill Robinson and Gail Cochrane). They usually have little training and experience in diagnostic theory and methodology, surgery, anaesthesiology, medical treatment, nursing, pain management and animal welfare. Diagnostic laboratories for animal medicine in China are limited and generally focus on research of specific pathogens, such as avian influenza, rather than providing clinical diagnostic services to support veterinary practitioners.

Furthermore, legislation controlling the activities of veterinarians within China is limited. Veterinary courses vary from a three-month animal handling course, to a two-year agriculture course, to a five-year veterinary degree. Anyone who has completed any of these courses may practise as a veterinarian. Legislation is in effect to prevent veterinarians from operating on people, but there is nothing to prevent anyone from operating on animals. (The latter is especially prominent in the context of research, where students with limited or no knowledge of animal anatomy, veterinary techniques and anaesthesia routinely perform *in vivo* surgery on animals.)

The gall bladder fistulation surgeries are usually performed by (human) doctors hired for the service, Chinese veterinarians, or technicians who have learned to perform the procedure. Animals receive no analgesia (pain control medication) during or after surgery, anaesthesia is inadequate and the choice of anaesthetic drugs inappropriate. There is no monitoring of physiologic parameters during anaesthesia, there is limited and frequently no practice or understanding of aseptic technique and the environmental conditions and medical care to which the animals are subjected post-operatively are grossly inappropriate, if not outright inhumane. Bear farmers refuse to reveal the survival rate of bears that undergo gall bladder fistulation surgery or even general morbidity and mortality data on their farms. Part of the reason for this is that medical records are not routinely kept in any animal facility, so accurate figures may simply be unavailable.

Ultimately, adequate veterinary services on bear farms are economically unfeasible. In order to care for bears on bile farms in a humane manner, particularly in consideration of the enormous medical expense of properly caring for these animals, operational costs would far outweigh the returns¹.

In short, veterinary expertise, animal husbandry practices and ethical standards with regard to animal use and care are currently inadequate in China for bear bile farming and captive breeding to be carried out under even remotely acceptable conditions. Moreover, the monitoring and regulation of bear farms for medical and husbandry practices are not feasible in China due to gross and currently insurmountable technical limitations and corruption. Even with regard to an issue as dangerous and personal to the Chinese as avian influenza, production and distribution of substandard vaccines, crooked accounting and deceitful record-keeping compromise efforts to control the epidemic in China (Cai, 2006). In an industry as lucrative as the bear bile business, which is subject at best to “regulations” rather than actual laws, and that escapes notice in a culture unaccustomed to paying attention to matters relating to animal welfare, consistent enforcement of high standards is unlikely.

¹ The care of captive Asiatic black bears at the AAF Bear Rescue Centre requires annual operating costs of approximately US\$6,500 per bear (excluding essential capital costs such as bear dens, hospital facilities and equipment). The current (official) operating costs for Chinese bear bile farms range from US\$33 to 3,000 per year per bear (mean US\$736±882). If these farms were to operate with acceptable levels of animal husbandry and veterinary care, at 1-2 kg bile production per bear per year, at a (domestic market) return of US\$240 to US\$3,000 per kg bile, a farm with 100 tapped bears would require annual operating costs of US\$650,000 for a (domestic retail) return of US\$24,000 to 300,000. This does not include costs that would be needed for good nursery facilities for breeding bears and cubs (assuming that the farm is self-sustaining, per regulations), essential capital costs and administrative costs for the farm. For bear bile farms to meet the medical needs of their bears, moreover, the veterinary costs would be even higher than those at the AAF Bear Rescue Centre (due to the continuous need for new and repeated surgeries, and treatment for chronic infections, wounds and other illness), and would thereby drive the cost of bile production even further beyond its economic return. Clearly, the industry is not economically viable.

GALL BLADDER FISTULATION AND BILE EXTRACTION METHODS

Inherent difficulties with long-term maintenance of gall bladder fistulas and bile extraction have driven the development of five different techniques in the 25 years of China's bear bile farming industry.

Latex catheter

The original method involves variations of a device constructed from a short metal or plastic tube and disc that anchors a narrow latex tube inside the gall bladder with the aid of a purse-string suture. The latex tube exits the hole in the fundus of the gall bladder, passes through the abdominal musculature and then beneath the skin along the length of the bear's flank, to emerge at the hip, where the free end is tied in a knot (Figure 2(a)). The advantage of this method is that the farmer works at the back end of the bear, away from the bear's teeth and the claws of its agile forepaws. Bile is suctioned out of the tube once or twice a day with the aid of a needle attached to a syringe. A maximum of 50 to 80 ml of bile can be obtained per day. The length and narrow lumen of the latex tube (Figure 2(b)) results in its frequent blockage by inspissated bile and pus.

Figure 2(a)



Figure 2(b)



Figure 2: (a) A bear anaesthetised in its original bear cage prior to performing a complete health check at AAF's Bear Rescue Centre. Note the latex catheter exiting from the left hip area.

Figure 2: (b) A latex catheter with associated latex tubing. Note the narrow diameter of the tubes.

Latex catheter with corset

An adaptation of the latex catheter method involves a bile collection bag secured to the bear's abdomen by a metal corset (Figure 3(a)). The latex catheter exiting the gall bladder is of a larger diameter than the flank-threaded tube and is secured to the abdominal muscle at the fistula with a metal clip (Figure 4). From there, the tube travels through the abdominal musculature to exit the skin from the fistula and into an old intravenous fluid bag (Figure 3(b)). Bile drips into the bag, which lies in a small metal box attached to the underside of a hinged flap in the corset. With the bear in a sternal position in the cage, the farmer opens the metal flap and replaces the bag with an empty one every one or two weeks. The 10 kg metal corset is attached to the bear with metal and leather straps and is a relentless source of irritation and trauma to the bear's body. Bears at the AAF Bear Rescue Centre have permanent scars as a result of wearing these corsets for years (Figure 3(c)). Clogged tubes and chronic infection make this system problematic.

Figure 3(a)



Figure 3(b)



Figure 3(c)



Figure 3: Bears wear metal corsets (a) that hold a bile collection bag in a flap at the belly (b). The latex catheter exits the gall bladder and feeds into the bag. Leakage of bile irritates the skin and the metal corset causes permanent scars on the bear's body (c). The scars are on the back and neck of the bear (the head is to the left of the picture).

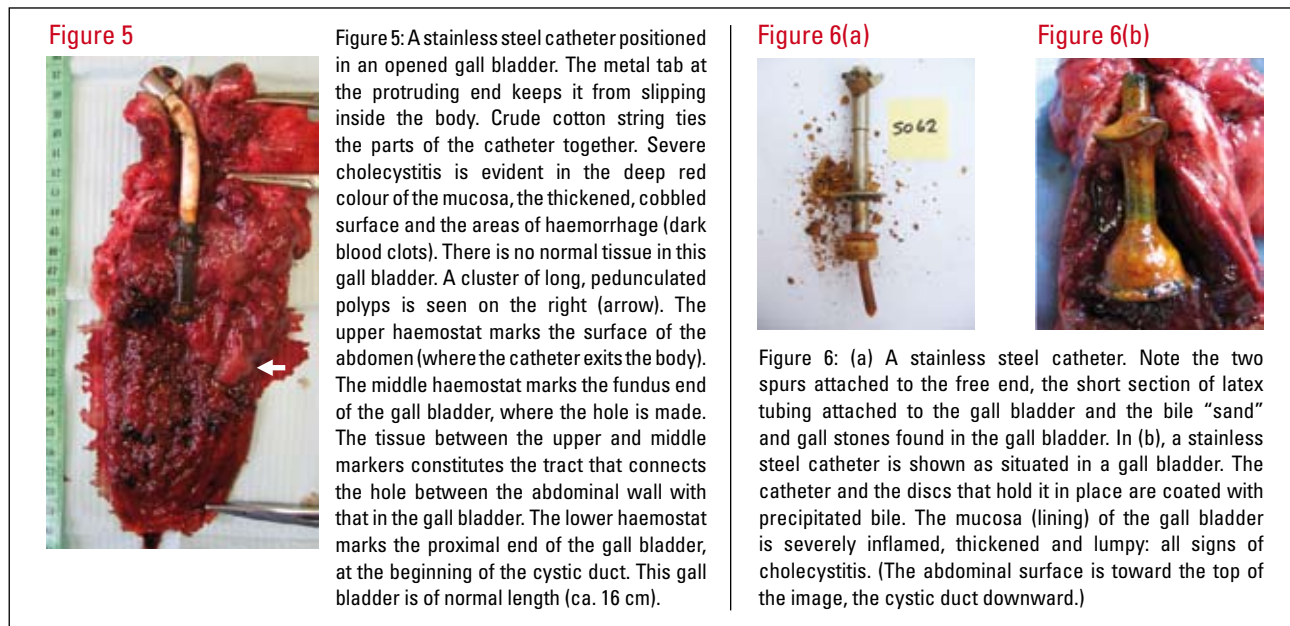
Figure 4



Figure 4: A latex catheter removed from a bear that wore a metal corset construction. The latex tube (on the right) had been cut short prior to the bear's shipment to the AAF Bear Rescue Centre: this is the end that emerged from the bear's abdomen into the bile collection bag. The crude cotton string that is also used as suture material holds the flexible latex tube to the hard plastic catheter that lies inside the gall bladder. The large metal ring was pierced through the end of the bear's sternum to hold the catheter in place. In other bears, latex catheters are secured in place with the cotton string. Each mark on the measuring tape indicates one millimetre.

Stainless steel catheter

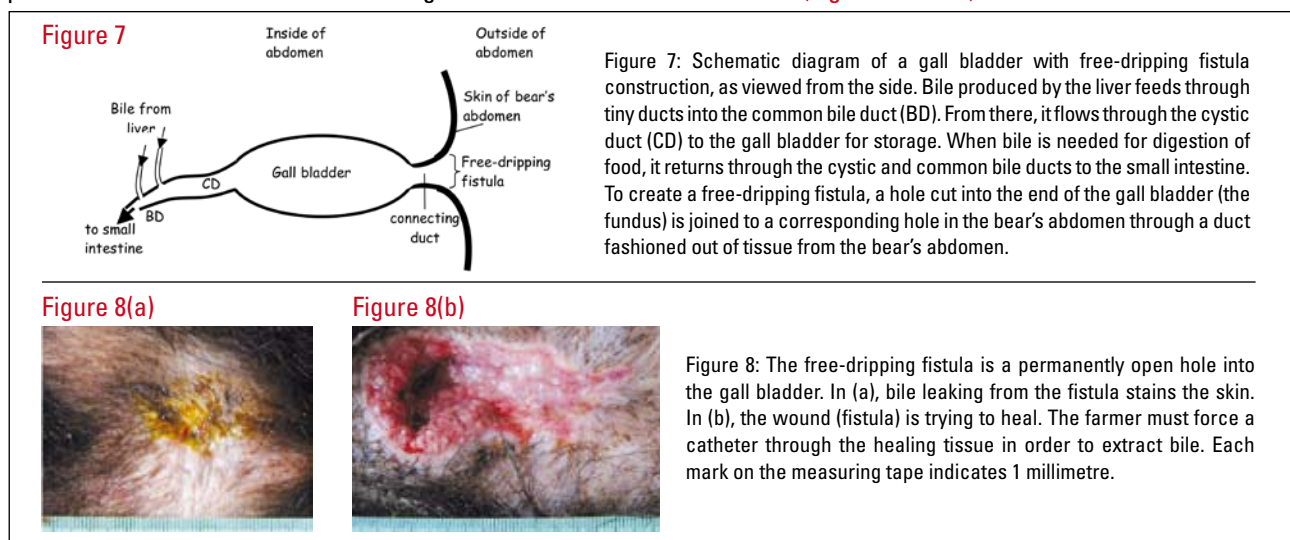
Complications with the latex tube methods led to the development of the stainless steel catheter system (Figure 5 & 6). The catheter is between 10 to 20 cm long and has two stainless steel discs placed 3 to 5 cm apart near one end. A short piece of latex tubing is sometimes attached to the terminal disc. This end is secured inside the gall bladder with the aid of a purse string suture so that the penultimate disc lies just inside of the fistula, beneath the abdominal muscle (Figure 6(b)), and the length of the catheter protrudes from the abdomen (Figure 6(a)). One or two metal spurs may project from the free end of the catheter and are intended to prevent the catheter from slipping into the gall bladder and to discourage the bear from chewing on it (Figure 5 & 6(a)). Cotton or lint is used to plug the open end to prevent leakage of bile between extractions. Bile is collected by restraining the bear in such a way that its abdomen is pressed against the bottom of the cage. The plug is then removed, allowing bile to drip into a bowl beneath the cage. A thin tube (again, unclean) may be inserted through the stainless steel catheter to facilitate drainage.



Free-dripping technique

Negative publicity associated with the worldwide distribution of photographs depicting catheterised bears (which followed exposure of the practice of bear bile extraction by AAF's Founder and CEO, Jill Robinson) motivated the Chinese government to encourage the free-dripping method of bile extraction in the mid-1990s.

To create the free-dripping fistula, a tube is constructed of tissue taken from within the bear's abdomen (presumably mesentery, but this has yet to be verified by the pathologist examining AAF's histopathology samples). This tube is then positioned to link the holes made in the gall bladder and the abdominal wall (Figures 7 and 8).



To extract bile from a free-dripping fistula, the farmer inserts a rubber or stainless steel tube into the hole. Bile then drips from the tube into a tray or is drawn out with a syringe. On larger farms (in front of visitors) the area of the fistula is given a quick wipe with a cloth or alcohol swab prior to bile extraction. Effectively, however, neither the bear's abdomen nor the instruments are cleaned prior to the operation. (Alcohol alone, particularly without first cleaning the catheter and for such a short duration of exposure, does not sterilise the instrument.) Between extractions, bile leaks onto the surface of the bear's abdomen. The caustic nature of bile causes chronic irritation and ulceration to the skin (Figure 1(d)).

Bears heal their wounds quickly and, as mentioned earlier, the farmer often has to make repeated attempts to force a bile collection tube or probe through tissue that obstructs the free-dripping fistula. Gall bladders are occasionally perforated by this operation, as evidenced by the lesions found at the time of cholecystectomy at the AAF Bear Rescue Centre. A misguided instrument may also bypass the gall bladder and enter the abdominal cavity directly. A ruptured liver and/or contamination of the abdominal cavity is a likely consequence, which results, at best, in localised abscesses, and, at worst, in diffuse (and ultimately fatal) peritonitis. Clearly the pain that the bear suffers during this procedure is severe.

Bear farmers and government officials maintain that the replacement of stainless steel or latex catheters with a tube made of the "bear's own body" precludes complications associated with the fistula and ensures a pain-free bile extraction experience for the bear. A Chinese CITES representative described the free-dripping fistula like a natural opening in a bear, in that it is "similar to the anus and can be blocked by muscle contraction" (Fan and Song, 1999). This statement epitomises the ongoing deceit of the farmers who continually invent new methods of bile extraction in an attempt to convince the government that bear farming is humane. It also demonstrates a lack of medical understanding and the violation of ethical principles necessary to maintain the bear farming industry. More importantly, it goes against the experience of bear farmers (and what they tell unofficial visitors): namely that the fistulas do develop ascending infections, and why, among other reasons, they confine the bears to cages (AAF and P. Li, unpublished data). Data and observations presented below establish that the free-dripping fistula is just as damaging to the health and well-being of the bear as the other bile extraction methods.

Regulations published by the Chinese Ministry of Forestry in 1996 ("Notice on strengthening the management and administration of bear farms") prohibit the use of "foreign materials" in the creation of the fistula and mandate the exclusive utilisation of the free-dripping technique for bear bile collection. This meant that all bears catheterised with latex or stainless steel tubes had to undergo conversion surgery to the free-dripping fistula. However, many bear farmers ignored the regulation because of the expense of conversion surgeries, their preference for latex or stainless steel catheters and their confidence that the regulations were – and are – unlikely to be enforced. For example, a recent (2006) visit by AAF to a large bear farm in Jilin Province revealed that all of the several hundred bears on the farm wore metal corsets and would therefore have latex catheters. Farmers at a large farm in Yunnan Province, whose 530 bears had stainless steel catheters, freely admitted to visitors from AAF in 2005 that, although the farm had six full-time veterinarians on staff, their efforts to convert stainless steel catheter systems to free-dripping fistulas in 70 bears failed and they had stopped trying. Most of the bears at the AAF Bear Rescue Centre were probably fistulated after 1996 and 62% arrived there with free-dripping fistulas. Many of these bears show evidence of having undergone more than one surgery – either because the previous structure had clogged and become unusable or to convert a latex or stainless steel catheter system to a free-dripping system, or both.

"Fake" free-dripping technique

The primary frustration to bear farmers with the free-dripping method is the difficulty in keeping the fistula patent. In 2005, AAF first began to see bears fistulated with the "fake" free-dripping method, which farmers were using to circumvent the


Figure 9

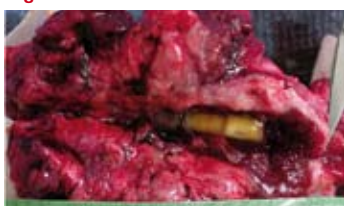

Figure 9: A "fake" free-dripping catheter situated inside the gall bladder. The scissor tip on the right marks the proximal end of the gall bladder, at the beginning of the cystic duct. This gall bladder is only about 4.5 cm long, indicating that the bear had undergone multiple surgeries to create new fistulas in a gall bladder that was severely diseased. The wall of this gall bladder is 10 times thicker than normal and the mucosa is congested and cobbled with polyps. There is no discernible lumen in which bile could collect. This bear was at the end of its useful life to the bear bile farmer. A piece of suture material covered in pus (upper left) was removed from this gall bladder as well. Each mark on the measuring tape indicates 1 millimetre.

1996 regulation (Figures 9 and 10). A short Perspex catheter is positioned in the gall bladder in a manner similar to the stainless steel catheter. The external end of the catheter, however, is cut flush with the surface of the abdomen or just beneath the skin. Unless the bear is very closely inspected, the clear plastic catheter is all but invisible and the hole in the bear's abdomen looks like a regulation free-dripping fistula.

Of the 65 bears that arrived at the AAF Bear Rescue Centre between January 2005 and June 2006, four had a "fake" free-dripping fistula. All four of these bears had come from the same bear farm. In these bears, a bulb at the inserted end of the Perspex tube prevented it from falling out (Figure 10(b)). The catheter is additionally secured with the aid of wire flanges that jut into the tissue between the gall bladder and the abdominal aperture. Extensive scar tissue and abscesses form around these flanges (described below).



PATHOLOGY ASSOCIATED WITH THE FREE-DRIPPING METHOD OF BILE EXTRACTION FROM BEARS

Pathology of the gall bladder

AAF veterinarians routinely remove the gall bladder of every fistulated bear that arrives at the AAF Bear Rescue Centre. In the first groups of bears rescued by AAF, only the damaged area of the gall bladder fundus that was associated with the fistula was removed, along with catheters and other foreign materials in the lumen. However, these bears invariably developed further complications, which necessitated the eventual removal of the entire gall bladder. A complete cholecystectomy is now performed on every tapped bear. As much of the cystic duct as possible is removed along with the gall bladder in order to prevent subsequent formation of gall stones in the distal end of the cystic duct.

The pathology associated with gall bladder fistulation and bile extraction progresses with time and ultimately leads to the premature death of the bear – sometimes even if bile extraction is discontinued. Of the nearly 200 tapped bears that have undergone medical rehabilitation at the AAF Bear Rescue Centre, 14 (42% of all deaths) have died of, or were euthanised for, irreversible pathologic processes directly attributable to bile extraction. An additional 16 bears (49% of all deaths) were euthanised for diseases that may have resulted from the chronic inflammation and infection associated with bile extraction (research to investigate this link is currently ongoing). **It is also clear that all methods of bile extraction – whether by implantation of a latex, stainless steel or Perspex catheter, or by free-dripping fistula – cause significant pathology and are equally damaging to the health of the bear.**

AAF has documented seven principle pathologic changes in the gall bladder of tapped bears: cholecystitis (inflammation and/or infection of the gall bladder wall), polyp formation on the mucosa (inner lining of the gall bladder), cholelithiasis (gall stones), the presence of foreign objects in the lumen of the gall bladder, strictures in the gall bladder wall, obstruction of the cystic duct and partial herniation of the gall bladder wall. The descriptions presented below are based on the gross examination of nearly 180 gall bladders removed by veterinarians at the AAF Bear Rescue Centre. Tissue sections are saved for histopathology from each cholecystectomy, post-mortem examination and other biopsies performed by AAF. These samples will be examined by a wildlife pathologist in the United States (pending the Chinese export permit for the histopathology samples), which will allow further insight into the nature and pathogenesis of the changes associated with bile extraction from bears.

Every gall bladder that AAF veterinarians have removed from bile farm bears shows evidence of cholecystitis, regardless of the method of bile extraction to which the bear has been subjected (Figures 5, 6(b), 9, 11(a), 11(b), 12, 13). Gall bladders from untapped bears have, of course, not been removed for examination, but ultrasonography indicates none of the abnormalities that are seen in fistulated gall bladders. Gross changes associated with cholecystitis include erythematous (reddened, inflamed) mucosa; a thickened gall bladder wall; necrosis of the gall bladder wall, particularly in areas in which gall stones have lodged; and pus mixed with bile in the lumen of the gall bladder.

Polyps occur in 68% of tapped gall bladders (69% of free-dripping; 62% of the other three methods combined; **Figures 5, 6(b), 9, 11(a) and 11(b)**). They vary in size from small, diffuse lesions that give the mucosa a cobbled appearance to long, pendulous clusters. The larger polyps may be as long as 5 cm and usually develop in and around the fistula in the fundus and the tract that connects the hole in the gall bladder with that in the abdominal wall. Polyps develop, presumably, in reaction to the chronic trauma and inflammation associated with the bile extraction procedure. In some of the gall bladders, polyps had grown so densely as to obstruct the outflow of bile either by extraction (**Figure 11(b)**) or through the normal route via the cystic duct.

Figure 11(a)

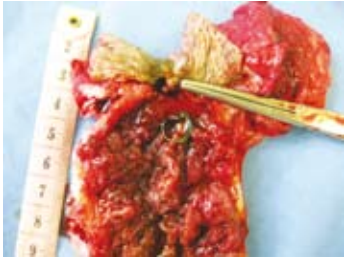


Figure 11(b)

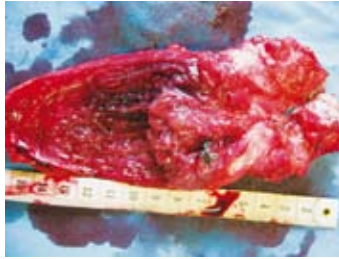

Figure 11(a): Shows a gall bladder wall totally covered with medium sized polyps. Note the small metal foreign object sitting in the gall bladder. The measuring tape marks centimetres.

Figure 11(b): This gall bladder had one very large polyp 4 cm long obstructing the free-dripping fistula. Note the piece of cotton thread suture material near the base of the polyp. The measuring tape marks centimetres.

The retention of bile results in the precipitation of bile crystals, or “sand” (the precursor to gall stones), and the development of bile sludge in the gall bladder. A bear farmer would not be able to collect bile from a gall bladder in this condition and the bear would have had to undergo another surgery to cut back the proliferated tissue and re-create the fistula in the shortened gall bladder. If the bear isn’t worth the trouble, it is left to die by starvation or killed for the sale of its body parts (paws, meat, fat and pelt).

Choleliths, or gall stones, develop from the precipitation of bile salts (**Figure 6(a) and 12**). Cholecystitis and bile retention may, as mentioned, initiate the development of gall stones, as may the presence of physical structures that serve as a nidus for precipitate aggregation (e.g. foreign objects, discussed below). Cholelithiasis occurs in 26% of AAF’s tapped bears (23% of free-dripping; 36% of the other three methods combined), and may present as any combination of sludge, single large stones, or collections of variably sized stones and “sand”. Stones may fill the entire lumen of the gall bladder, which would significantly interfere with the ability of the farmer to extract bile (**Figure 12**). Gall stones are also excruciatingly painful.

Figure 12

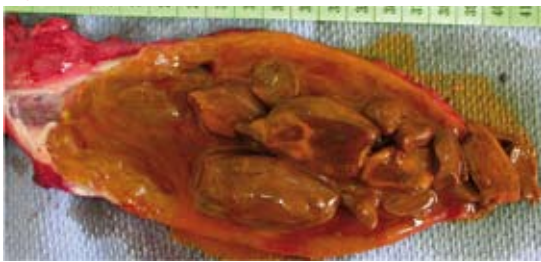

Figure 12: Gall stones fill the lumen of a gall bladder removed from a bear that had been used for bile extraction. It would have been difficult for the farmer to obtain bile from this bear.

Foreign objects lodged in the wall and lumen of the gall bladder are found in 22% of tapped gall bladders (21% of free-dripping; 24% of the other three methods combined; **Figures 9, 10(b), 11(a), 11(b) and 13**). These are usually pieces of suture material or pieces of latex tubing. The braided cotton string that is used as suture material (which is usually not sterilised prior to use) is entirely inappropriate by Western surgical standards. The sections of string lodged in the wall of the gall bladder are usually encased in abscesses. (Why they were placed there at all is unclear.) Pieces of rubber tubing and other foreign material in the lumen of the gall bladder are generally encrusted with bile crystals.

Figure 13

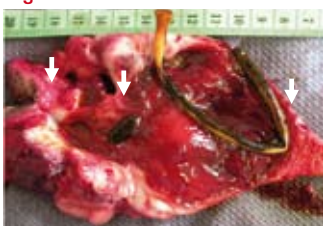


Figure 13: Foreign objects are a common finding in gall bladders of bears from bear bile farms. A latex catheter and bits of suture material had been left inside this gall bladder when the bear’s fistula was converted from a latex catheter to a free-dripping system. Multiple re-fistulation surgeries resulted in the short length of the gall bladder. Chronic infection and trauma caused the cholecystitis. The hole entering the abdomen is marked by the arrow on the left; between this and the next arrow is the tract that connects the abdominal wall to the hole in the end of the gall bladder (arrow 2nd from left). The right-most arrow marks the proximal end of the gall bladder, at the beginning of the cystic duct. The measuring tape marks centimetres.

Partial herniation of the gall bladder wall is probably usually caused by a catheter or probe that is stabbed through the fistula and inadvertently impales the gall bladder wall. Herniation may also be caused by mishandling of the gall bladder during the fistulation surgery or any other trauma or chronic pathologic process that weakens an area of the gall bladder wall. An eventual consequence of such a lesion may be the complete herniation, or rupture, of the gall bladder and the leakage of bile into the abdominal cavity. Bile is caustic and the resulting bile peritonitis is extremely painful and fatal.

Abscesses on the outer surface of gall bladders suggest previous areas of bile leakage that the bear's immune system had managed to contain. Strictures of the gall bladder wall are occasionally seen as well. The etiology of these is unclear, but probably involves scarred tissue from previous wounds.

Pathology of abdominal structures other than the gall bladder

Abdominal tissues surrounding the gall bladder invariably show evidence of injury that extends beyond the gall bladder itself. Common findings include abscesses, masses of scar tissue, foreign objects, fistulous tracts, adhesions, herniation of the abdominal wall, displaced organs and, at worst, peritonitis and cancer associated with the liver.

The short tract connecting the gall bladder to the abdominal wall in fistulated bears is often encased in a mass of scar tissue that can measure as much as 25 cm in diameter. The mass may surround the entire gall bladder, particularly if the bear has undergone multiple surgeries. Fibrous masses are found in 32% of fistulated bears (22% of free-dripping; 56% of the other three methods combined). The wire flanges that secure the Perspex catheters of "fake" free-dripping fistulas are embedded in these fibrous masses: their presence causes sufficient irritation to affect the deposition of layers and layers of scar tissue in the body's effort to wall off the traumatising objects. One latex catheter had been secured to the xyphoid process with a wire ring. The xyphoid process is a cartilaginous structure at the end of the sternum. In this bear, the chronic trauma of the wire had resulted in the ossification of the structure, which had to be amputated in order to remove the ring. In another bear, the wire flanges were lodged in an adjacent lobe of the liver. The constant irritation of these anchors must be assumed to cause pain. Abscesses are usually found throughout the masses surrounding the gall bladder and connecting tract.

Abscesses are found in 29% of fistulated bears (31% free-dripping, 24% of the other three methods combined) and occur throughout the abdomen (omentum, liver, peritoneum, mesentery, gall bladder wall), in the abdominal muscle layers and the overlying skin. They may be large or small, single, multiple, clustered or scattered. Most are of a thick, caseous material and some are old enough to have begun to calcify. Some abscesses harbour foreign material, most often pieces of the thick cotton suture material described above. One abscess surrounded the terminal 3 cm of a stainless steel extraction catheter that presumably had broken off when the farmer stabbed the catheter through the free-dripping fistula and missed the gall bladder. One can imagine the violent response of the bear to this impalement and the consequent fracture of the catheter. A toothpick was found embedded in the omentum of another bear's abdomen.

The muscle and skin surrounding the fistula are common sites of suture abscesses (Figure 10(a)), and often harbour fistulous tracts or pockets of bile or mucous as well. These tracts are associated with subcutaneous leakage of bile or chronic infection. (Bile is extremely caustic and causes severe irritation and inflammation of tissues.) Poorly constructed gall bladder fistulas result in bile leaking into the muscle layers of the abdomen or under the skin to establish these tracts. One bear had a web of these tracts over most of his abdomen and thorax. Some of the tracts are found as fibrous and even calcified structures that formed as a result of the body's efforts to contain the contamination. Their advanced fibrosis and ossification gives evidence to their chronicity: the bears had lived with the inflammation and pain of these lesions for years.

Adhesions between the gall bladder (or the mass around it) and the surrounding mesentery or adjacent organs occur frequently in fistulated bear abdomens that AAF veterinarians have explored (42% total, 37% free-dripping, 54% of the other three methods combined). The liver is often tightly and extensively adhered to the gall bladder mass, such that the distal areas of affected lobes may be completely engulfed and abscessed. In some bears it appears that omentum and mesentery were used to "wrap" the tract connecting the holes in the gall bladder and the abdominal wall. Abdominal organs are sometimes displaced such that the pancreas is found on the far right side of the abdomen (it normally lies on the left), the stomach pulled caudally and to the right, and loops of intestine caught in torn strips of mesentery and posing the threat of bowel strangulation and a horrible death.

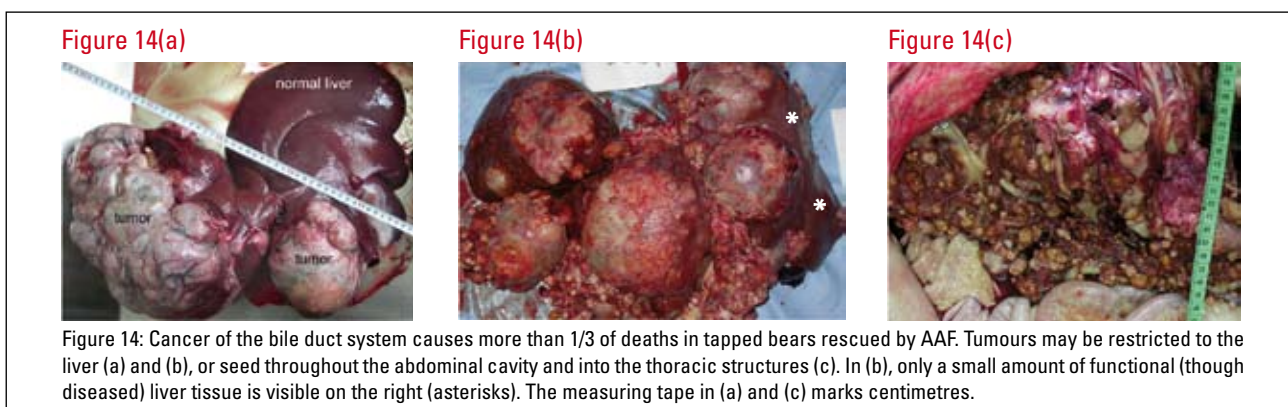
Herniation of the abdominal wall is found in 28% (32% free-dripping, 19% of the other three methods combined) of fistulated bears (never in untapped bears). These hernias result from the inability of the abdominal wall to heal properly after it has been cut open for gall bladder fistulation. Poor surgical technique, infection and failed sutures are the most likely causes. Hernias range in length from a few centimetres to 75% of the length of the abdomen. In some bears, the abdominal organs are held in place only by the skin; in others, a fibrous sheath has formed between the separated margins of abdominal muscle to hold in the contents of the abdomen. The simple movement of one bear from its body-sized bear farm cage to a larger cage on arrival at the AAF Bear Rescue Centre caused the thin membrane covering the bear's hernia to rupture and necessitated emergency surgery. This bear clearly had not moved from its small cage in a very long time.

Bears are incredibly resilient animals - physically, physiologically and emotionally. It is difficult to imagine any other creature that would survive the conditions of bile farming for more than a few weeks, let alone for years. The rescued bears are extremely responsive to both medical and behavioural rehabilitation at the AAF Bear Rescue Centre. They do, however, succumb to two conditions, regardless of the surgical and medical efforts to save them: peritonitis and cancer of the biliary system.

Bile farm bears develop peritonitis as a direct result of bile leakage into, or bacterial contamination of, the abdominal cavity due to poor surgical technique and dismal post-operative conditions (or both). As stated, peritonitis is always fatal in these bears, and is the cause of 32% of deaths in tapped bears at the AAF Bear Rescue Centre. Bile peritonitis may present as diffusely yellow, inflamed tissues throughout the abdomen with varying degrees of ascites or suppuration. Even if the source of bile leakage is removed, the bear never recovers fully and eventually dies of complications related to peritonitis. Bears with infectious peritonitis may also live for several months as the condition worsens, often with little overt clinical sign other than a reduction in appetite in the latter stages of illness. The abdominal cavities in some of these bears have released as much as 7 litres of pus on post-mortem examination.

AAF veterinarians have learned to recognise the subtle signs of peritonitis in bears and quickly perform an exploratory laparotomy on animals suspected of the condition. Bears with peritonitis are now euthanised at the time of diagnosis due to the poor prognosis of the condition. On bear farms, peritonitis is rarely, if ever, diagnosed, and if a bear's illness does not respond to the farmer's remedies (which peritonitis would not do), the farmer ceases to feed the moribund animal and continues to extract its bile until it dies (or it is slaughtered for its valuable parts). Humane euthanasia for animals is not yet a concept with which the Chinese are comfortable. Even if it were, a bear farmer would not invest in such a final expense for an animal that would no longer be a source of revenue.

More than one third of deaths of tapped bears at the AAF Bear Rescue Centre are due to cancer in the hepatobiliary system (Figure 14). Sloth bears and perhaps other species of Asian bears appear to have a predilection for developing biliary carcinomas (Moulton, 1961; Montali et al., 1981; Gosselin and Kramer, 1984), but this has rarely been documented in Asiatic black bears (Fitzgerald and Bennett, 1995). The cases in zoos, moreover, are older bears, while the affected bile farm bears are young or middle-aged. That it should be the cause of 37% of deaths is extraordinary in any case. AAF's veterinarians hypothesise that the etiology of the cancer is related to the chronic inflammation, infection and trauma caused by bile extraction. Research is under way to investigate this hypothesis. In another context, consideration must be given to the potential effects on humans of the consumption of bear bile that is so contaminated with pus and inflammatory material.



CONCLUSION

The farming of bears for bile extraction is unsustainable, violates every principle of animal welfare, is inhumane by any criteria, and causes a variety of acute, chronic and life-threatening medical complications to the bears. In short, the practice is unacceptable in any human society that wishes to be considered civilised. Virtually all Chinese visitors (including some ex-bear farmers who have given up their business) who tour the AAF Bear Rescue Centre and who become informed about the facts of bear farming recognise its inhumanity and agree that it should end. Among young urban Chinese, in particular, there is a growing interest in environmental stewardship and wildlife conservation. With their unprecedented access to international news, information and ideas, this group is becoming increasingly active and outspoken on these issues. The perception of animals and the attitude toward animal welfare will certainly improve in the coming generations in China.

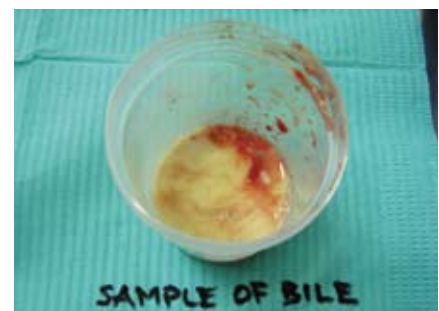

Jasper spent more than 10 years on a bear farm in this crush cage. Today, he is enjoying a life of freedom at AAF's Bear Rescue Centre in China.

Money, however, is an enormous force and until the Chinese government outlaws bear bile farming and thereby legislates to end this lucrative business, it will continue. History and human nature dictate that illegal bear farms and poaching of wild bears will continue, regardless of laws, and that battle must continue to be fought. China's 25 years of bear farming have demonstrated that it is impossible to conduct such a practice in a manner that is even remotely ethical and that the industry does not prevent poaching. Bear bile farming must stop.

At the heart of this issue lies the cultural devotion to wildlife products and the increasing means to indulge this devotion. The maintenance of traditions and cultural heritage is, of course, desirable, but the human species has developed a world in which it now must choose what it values. Few questions regarding humanity's use of natural resources are simple: most cultures struggle with the balance between the consumption of resources and the maintenance of certain lifestyles. The responsibility for making that choice lies with every single person in the world, whether these choices relate to the use of energy, furthering human overpopulation, the production of pollutants, or the consumption of products for which animals must suffer. Trade in wildlife parts and products - legal or otherwise - will continue as long as there is a market for them; and there will be a market as long as "traditional" values are not challenged and modern societies continue to make uninformed choices. Consumers must choose whether they want to use bear bile and thereby threaten wild bears and condemn captive bears to lives of torment, or learn to live without bear bile. This is the choice.

Professor Liu Zhengcai writes (Liu, 2004), "Chinese Traditional Medicine theory highly praises the philosophy that we are part of nature and promotes the harmonious relationship between humans and nature. Wild animals are an important part of this relationship and play the role of maintaining an ecological balance and complementing a good environment for human beings. Protecting wild animals is protecting nature and ourselves. As members of the Traditional Chinese Medicine community, we work for the benefit of people's health. It is our responsibility as physicians to protect wild animals and to help rescue bears by refusing to use wild animals parts, such as bear bile, in our prescriptions."



Contents of a gall bladder from a bile farm bear. This is nearly all pus and very little bile.

Chinese doctors such as Professor Liu agree, moreover, that bile produced on farms is tainted with its violation of the fundamental principle of harmony with nature on which TCM is based. Natural harmony is destroyed when the bears suffer physical and mental illness from being used as machines, and by the pus and other potentially toxic substances extracted from the gall bladders of sick and suffering bears.

In the final analysis, it must be emphasised that the manufacture of no other product consumed by humankind requires an animal to undergo major surgery and then to live with permanently open wounds from that surgery, let alone under conditions of such cruelty as are found on bear bile farms.

As professionals who study, work with and respect nature and animals, we hold a great potential to assist people who are working through a cultural transition with regard to the use of and attitude toward animals. Let us honour our collective strength and encourage the Chinese government to outlaw bear farming and the public to stop using bear bile.

ACKNOWLEDGEMENTS

The Animals Asia Foundation would like to offer sincere gratitude and thanks to the China Wildlife Conservation Department in Beijing and the Sichuan Forestry Department in Chengdu for their valuable help and assistance since October 2000 in rescuing 219 previously farmed bears and in the development of the Sichuan Long Qiao Black Bear Rescue Centre in Chengdu. We would also sincerely like to thank the Central Forest Protection Department in Hanoi and the Ministry of Agriculture and Rural Development for their kind assistance in the ongoing development of our new Bear Rescue Sanctuary in Vietnam.

Literature citations

- Berkhoudt, K. (1999). Survey of bear trade in Europe. Proceedings of the Third International Symposium on the Trade in Bear Parts, Seoul, Korea, 26-28 October, pp. 88-97.
- Cai, J. (2006) Bird flu whistle blower gets jail term for graft. South China Morning Post, Hong Kong. 10 July.
- Fan, Z. and Song, Y. (1999). The development of bear farming in China. Proceedings of the Third International Symposium on the Trade in Bear Parts, Seoul, Korea, 26-28 October, pp. 100-109.
- Fitzgerald, S.D. and Bennett, R. (1995). Biliary carcinoma and hepatocellular carcinoma in an Asiatic black bear. Proceedings of the Joint Conference American Association of Zoo Veterinarians, Wildlife Disease Association, American Association of Wildlife Veterinarians, East Lansing, MI USA, pp. 342.
- Garshelis, D.L. (2002) Misconceptions, ironies, and uncertainties regarding trends in bear populations. *Ursus* 13: 321-334.
- Ge Gabriel, G. (1999). A bitter medicine: the use of bear bile in China. Proceedings of the Third International Symposium on the Trade of Bear Parts, Seoul, Republic of Korea, 26-28 October 1999, pp. 116-120.
- Gosselin, S.J. and Kramer, L.W. (1984). Extrahepatic biliary carcinoma in sloth bears. *Journal of the American Veterinary Medical Association* 185: 1314-1316.
- Lee, Y.-J. (1999). The use of bear bile as medicine versus tonic. Proceedings of the Third International Symposium on the Trade in Bear Parts, Seoul, Korea, 26-28 October, pp. 122-126.
- Liu, Z. (2004). TCM history shows that bear bile is not a necessary medicine. Proceedings of the 19th International Congress of Zoology, Symposium: Bear Farming. Beijing, China, pp. 46-48.

- Maas, B. (2000) The veterinary, behavioural and welfare implications of bear farming in Asia. World Society for the Protection of Animals, London.
- Montali, R.J., Hoopes, P.J. and Bush, M. (1981). Extrahepatic biliary carcinomas in Asiatic bears. *Journal of the National Cancer Institute* 66: 603-608.
- Moulton, J.E. (1961). Bile duct carcinomas in two bears. *The Cornell Veterinarian* 51: 285-293.
- Phillips, T. and Wilson, P. (2002) The bear bile business: the global trade in bear products from China to Asia and beyond. World Society for the Protection of Animals, London.
- Pong, S., Lo, Y.W. and Ho, K.C. (1999). Herbal alternatives to bear bile. *Proceedings of the Third International Symposium on the Trade in Bear Parts*, 26-28 October, pp. 154-157.
- Raloff, J. (2005). A galling business: the inhumane exploitation of bears for traditional Asian medicine. *Science News Online* 168: 250.
- Roberts, A. (1999). A case for a uniform global ban on the trade in bear parts and derivatives (a perspective from the United States). *Proceedings of the Third International Symposium on the Trade in Bear Parts*, Seoul, Korea, 26-28 October, pp. 138-152.
- Robinson, J. (1994). Conference summary. *Proceedings of the Third East Asiatic Bear Conference*, Beijing, China, 4-8 August, pp. 1-15.
- The Association of Chinese Medicine and Philosophy. (1994) The herbal alternatives to bear bile in Chinese medicine. EarthCare Society, Hong Kong. 107pp.
- van Biema, D. (1994). The killing fields. *Time*: 50-51.
- Wang, G.J. (1994). Protection and use of bear in China. *Proceedings of the Third East Asiatic Bear Conference*, Beijing, China, 4-8 August, pp. 15.
- Williamson, D.F. (2002) In the black: status, management and trade of the American black bear (*Ursus americanus*) in North America. TRAFFIC North America, 161pp.